

## AMD National Knowledge Week – June 2007

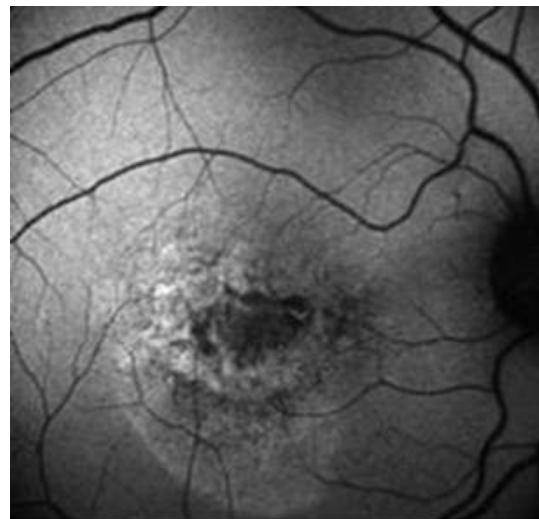
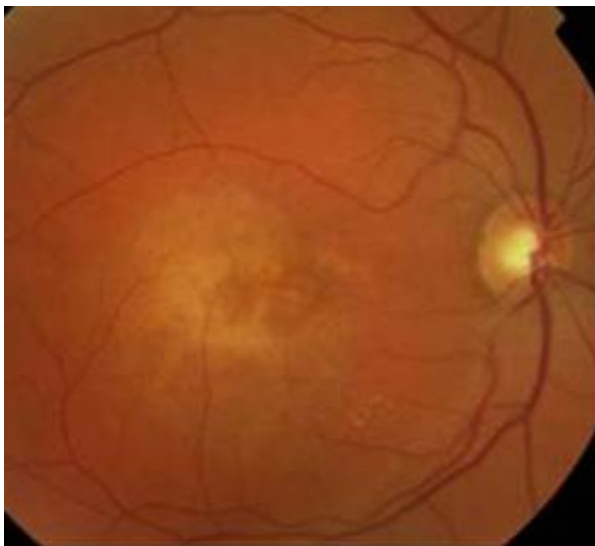
### What is the role of AF in the diagnosis of AMD?

Samantha Mann MD, MRCOphth, Specialist Registrar,  
Moorfields Eye Hospital NHS Foundation Trust

**Autofluorescence (AF) imaging** is a relatively newer, fast imaging technique which has been less extensively investigated. Its role in the diagnosis of various phenotypes of age related macular disease (AMD) as reported in observational studies is summarised here.

#### AF for Choroidal neovascular membranes (CNV)

- AF imaging of CNV is less well characterised than that for geographic atrophy (GA).[\[1,2\]](#)
- In general, little data exist to differentiate the different phenotypes of CNV with AF.[\[3\]](#)
- AF outlines a greater total area of the CNV lesion than that evident from fluorescein angiography (FFA), suggesting that this may provide a more accurate delineation of the lesion.[\[4\]](#)
- Increased AF may be seen adjacent to leaking areas of CNV seen on FFA.[\[4\]](#)
- Increased AF may represent proliferation of RPE cells around the lesion or debris within macrophages.[\[3,4\]](#)
- RPE may be intact with preserved AF in early CNV lesions, but is lost in late lesions with disciform scars.[\[4\]](#)
- There appears to be a different pathogenesis for the development of CNV with no increased AF occurring before its development.[\[3\]](#)



**Figure 1: Colour Fundus Photograph (right) and AF image (left) of occult CNV**  
Courtesy of Miss S Mann's MD thesis collection

## AF for Retinal Pigment Epithelial Detachment (PED)

- Retinal pigment epithelial detachments (PED) have been shown to have relatively normal levels of autofluorescence over the lesion itself (see Figure 2) which could be explained by the fact that PED's occur as a result of changes to Bruch's membrane with the anatomy and function of the RPE remaining relatively undisturbed.[\[4\]](#)
- PED's older than 6 months have shown a mild, diffusely increased autofluorescence corresponding exactly with the detached area and this persisted for 2 months after the detachment had flattened.[\[5\]](#)
- RPE tears –the area of denuded RPE appears dark with absence of AF and the rolled RPE gives a heterogeneous pattern with an intensity similar to background AF. The AF signal may arise as a combination of RPE lipofuscin and blockage from melanin within the RPE.[\[6\]](#)

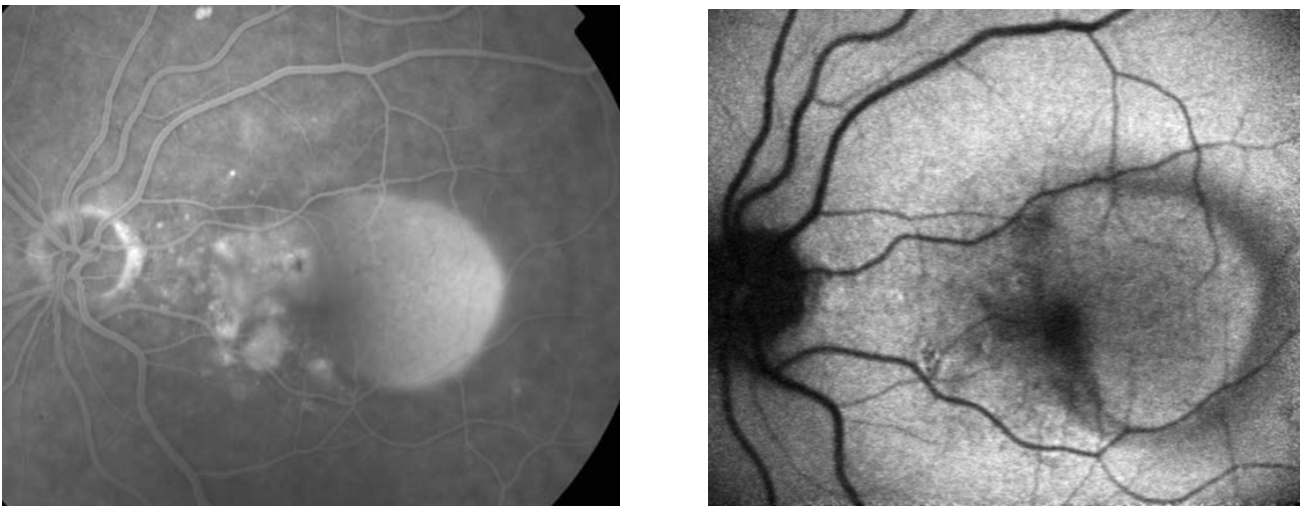
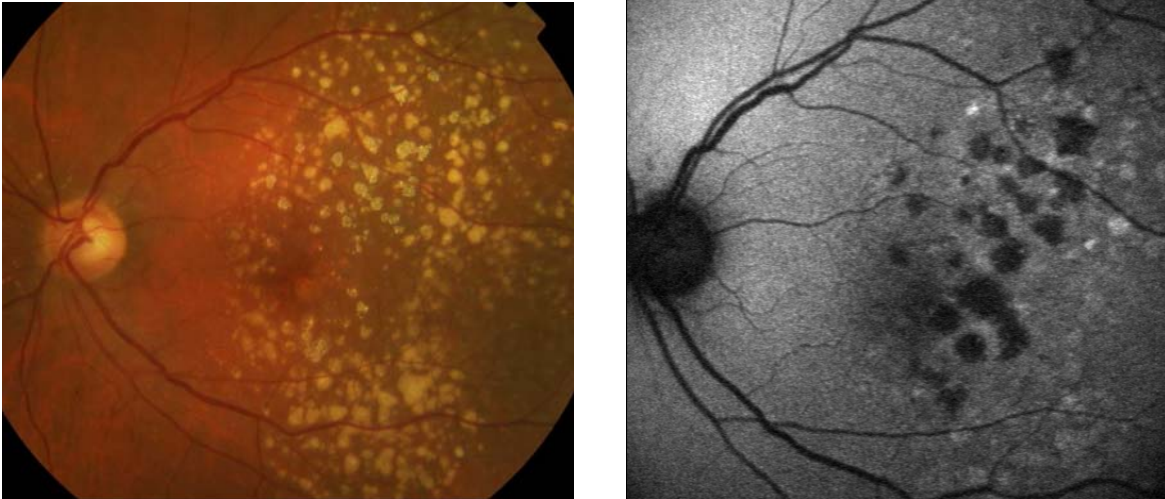


Figure 2:

**Fundus fluorescein angiogram (right) and AF image (left) of Retinal Pigment Epithelial Detachment and adjacent CNV lesion. Courtesy of Miss S Mann's MD thesis collection**

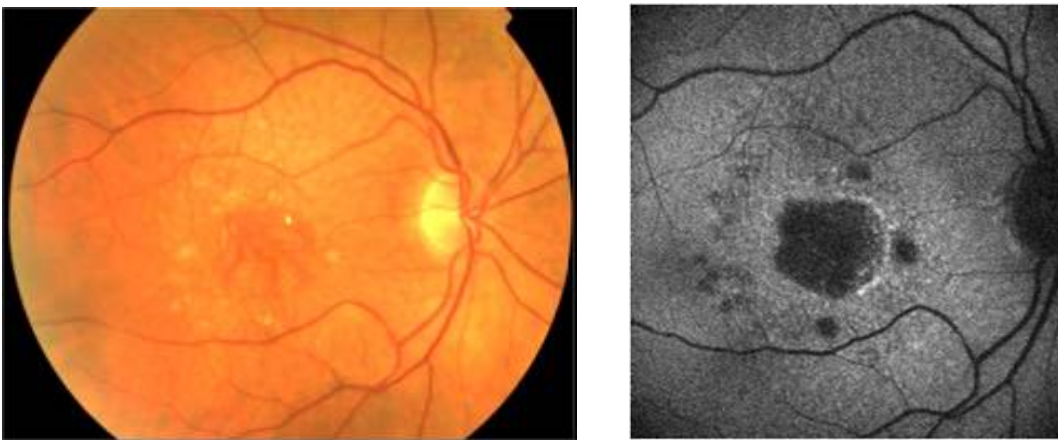
## AF for Geographic Atrophy (GA)

- Geographic atrophy is associated with decreased autofluorescence corresponding to areas of RPE atrophy and photoreceptor loss which is symmetrical between eyes.[\[7\]](#)
- Areas of increased AF at the posterior pole, observed around areas of atrophy may precede the development and enlargement of further atrophy.[\[8,9\]](#)
- AF may therefore play a role in detecting those at high risk of visual loss from further enlargement of areas of GA.
- AF is particularly useful at detecting smaller areas of atrophy that can be obscured by drusen on the colour image.[\[10\]](#)



**Figure 3:**

**Colour fundus photograph (right) and AF imaging (left) of Geographic Atrophy with drusen Courtesy of Miss S Mann's MD thesis collection**



**Figure 4:**

**Colour fundus photograph (right) and AF imaging (left) of Geographic Atrophy with surrounding increase in autofluorescence. Courtesy of Miss S Mann's MD thesis collection**

## **SUMMARY of the role of AF in AMD diagnosis**

Autofluorescence imaging is a relatively newer non-contact, fast imaging technique which has been less extensively investigated. Its use appears to be primarily aimed at detecting areas of increased *AF in eyes with GA which provides diagnostic and prognostic information regarding disease progression.*[\[11\]](#) *The technique also very easily detects areas of atrophy at the macula as dark areas, especially when obscured by drusen.* Quantitative analysis is also possible with computer driven planimetry techniques and this would be invaluable when assessing GA as part of a trial or study.[\[10\]](#) AF in PED and CNV have not been studied sufficiently to be able to comment on its use in diagnosis. AF may however play a role in RPE

tear diagnosis as it is easy to detect [\[6\]](#) and avoids the need for a fluorescein angiogram. Further larger studies calculating sensitivity and specificity of diagnosis of AMD are needed before AF can be recommended as a diagnostic test in isolation.

## References

1. Smith RT, Chan JK, Busuico M, Sivagnanavel V, Bird AC, Chong NV. Autofluorescence characteristics of early, atrophic, and high-risk fellow eyes in age-related macular degeneration. *Invest Ophthalmol Vis Sci.* 2006;47(12):5495-5504. [\[abstract\]](#)
2. Einbock W, Moessner A, Schnurrbusch UE, Holz FG, Wolf S; FAM Study Group. Changes in fundus autofluorescence in patients with age-related maculopathy. Correlation to visual function: a prospective study. *Graefes Arch Clin Exp Ophthalmol.* 2005;243(4):300-305. [\[abstract\]](#)
3. McBain VA, Townend J, Lois N. Fundus autofluorescence in exudative age-related macular degeneration. *Br J Ophthalmol.* 2007;91(4):491-6. [\[abstract\]](#)
4. Dandekar SS, Jenkins SA, Peto T, Scholl FG, Sehmi KS, Fitzke FW et al. Autofluorescence imaging of choroidal neovascularization due to age-related macular degeneration. *Arch Ophthalmol.* 2005;123(11):1507-1513. [\[abstract\]](#)
5. von Ruckmann A, Fitzke FW, Bird AC. Fundus autofluorescence in age-related macular disease imaged with a laser scanning ophthalmoscope. *Invest Ophthalmol Vis Sci.* 1997;38(2):478-486. [\[abstract\]](#)
6. Karadimas P, Paleokastritis GP, Bouzas EA. Fundus autofluorescence imaging findings in retinal pigment epithelial tear. *Eur J Ophthalmol.* 2006;16(5):767-769. [\[abstract\]](#)
7. Bellmann C, Jorzik J, Spital G, Unnebrink K, Pauleikhoff D, Holz FG. Symmetry of bilateral lesions in geographic atrophy in patients with age-related macular degeneration. *Arch Ophthalmol.* 2002;120(5):579-584. [\[abstract\]](#)
8. Holz FG, Bellmann C, Margaritidis M, Schütt F, Otto TP, Völcker HE et al. Patterns of increased in vivo fundus autofluorescence in the junctional zone of geographic atrophy of the retinal pigment epithelium associated with age-related macular degeneration. *Graefes Arch Clin Exp Ophthalmol.* 1999;237(2):145-152. [\[abstract\]](#)
9. Holz FG, Bellman C, Staudt S, Schütt F, Völcker HE. Fundus autofluorescence and development of geographic atrophy in age-related macular degeneration. *Invest Ophthalmol Vis Sci.* 2001;42(5):1051-1056. [\[abstract\]](#)
10. Sunness JS, Ziegler MD, Applegate CA. Issues in quantifying atrophic macular disease using retinal autofluorescence. *Retina.* 2006;26(6):666-672. [\[abstract\]](#)

11. Schmitz-Valckenberg S, Bindewald-Wittich A, Dolar-Szczasny J, Dreyhaupt J, Wolf S, Scholl HP et al. Correlation between the area of increased autofluorescence surrounding geographic atrophy and disease progression in patients with AMD. Invest Ophthalmol Vis Sci. 2006;47(6):2648-2654. [\[abstract\]](#)